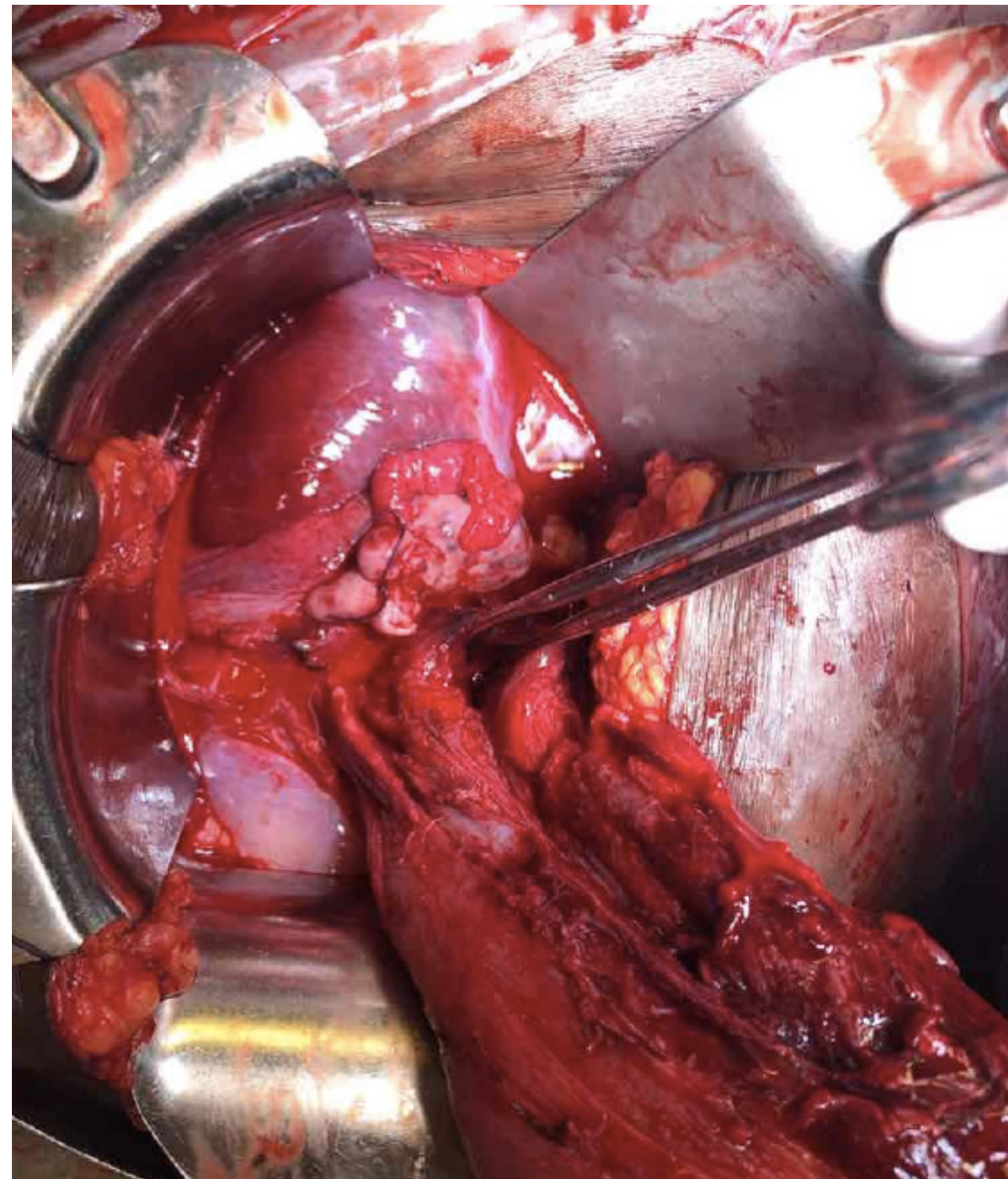


Introduction

Uterine rupture is morbid obstetric complication that is defined as a full thickness defect of the uterine wall and serosa (8). There are two categories of uterine rupture: rupture in the scarred uterus and rupture in the unscarred uterus (8). We present a case of a uterine rupture in a seemingly healthy uterus



Case Report

Our patient was a 26 year old G3P3003 female with no significant past medical history who underwent an uncomplicated labor course resulting in a spontaneous vaginal deliver of 3260 g baby girl. Her postpartum course was complicated by hemorrhage. After delivery she received cytotec, hemabate and additional Pitocin for lower uterine segment atony. However the bleeding persisted so the decision was made to deploy a Bakri balloon. The balloon was eventually placed after multiple attempts with immediate improvement in tone and bleeding. Approximately twenty minutes after placement patient exhibit signs and symptoms of hemorrhagic shock with blood pressure in the 60's/30's and altered mentation. She was emergently taken to the operating room for an exploratory laparotomy. Large bore intravenous access was obtained. Institutional massive transfusion protocol was initiated. Intra-operatively she was found to have a large, full-thickness defect was noted at the right aspect of the lower uterine segment. There was some difficulty achieving hemostasis and ultimately the decision was made to move forward with a hysterectomy. Total blood loss was estimated to be approximately 8 L with 5L loss intra-operatively. She was resuscitated with 8 units of packed red blood cells, 6 units of fresh frozen plasma, 1 unit of cryoprecipitate and 1 pack of platelets. Post-operatively she was transferred to the ICU where she was extubated on postoperative day 1. She was ultimately discharged home on postoperative day 5.

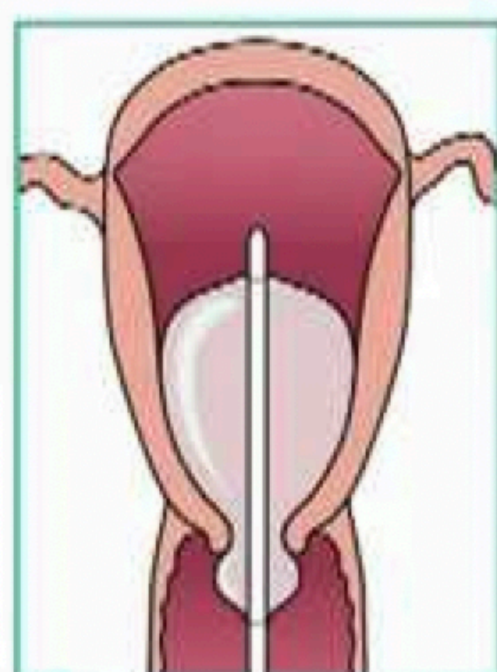
Discussion

Uterine rupture is a morbid but rare condition especially in the healthy uterus. American studies by Gibbins et al demonstrated that 4.54 ruptures per 100,000 deliveries and these patients were more likely to require blood transfusion and hysterectomy (2). In most of the reported cases in the literature were ruptures in the gravid uterus. The risk factors in these cases include the use of uterotonics during induction of labor, fetal macrosomia, multiparity, maternal age, and previous obstetric surgical procedures (1,2).

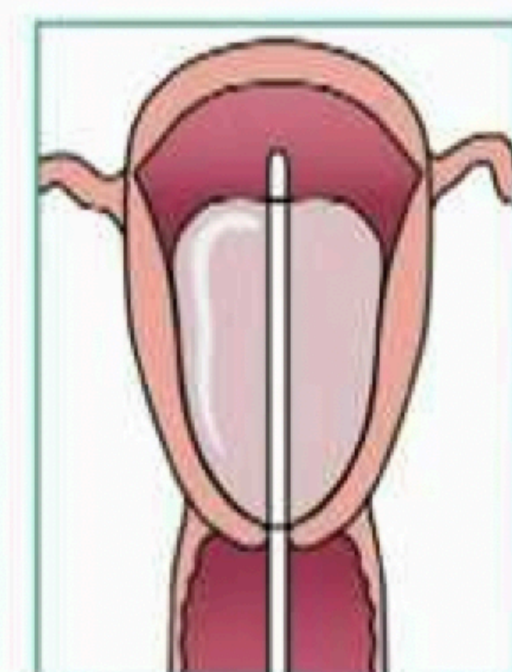
However, in our case the patient already had a spontaneous vaginal delivery with postpartum hemorrhage not controlled with uterotonics, methergin or hemabate. Impaired collagen synthesis or recent steroid usage is possible explanations, but neither was reported in her medical history (3). There are reported cases of a Bakri balloon causing rupture of the uterus (4,6). This represents to most probable cause of her uterine rupture, as she required the balloon to be placed twice with an increase in hemorrhage with symptoms of shock approximately twenty minutes after successful placement.

Due to the high morbidity there should be a multidisciplinary approach to the care of the patient. Signs and symptoms should be quickly recognized. These may include increased abdominal pain, maternal tachycardia, altered mental status and coagulopathy (5,7).

Transvaginal placement Procedural Steps and Animation



Incorrect



Correct

References

1. Al-Zirqi, I., Kjersti Daltveit, A., Forsén, L., Stray-Pedersen, B., Vangen, S. Risk factors for complete uterine rupture. American Journal of Obstetrics & Gynecology FEBRUARY 2017
2. Gibbins KJ, Weber T, Holmgren CM, et al. Maternal and fetal morbidity associated with uterine rupture of the unscarred uterus. Am J Obstet Gynecol 2015; 213:382.e1.
3. Grigoriadis C, Tympa A, Delivoria V, Baka S, Theodoraki K. Long-term steroid treatment: a potential risk factor for uterine rupture during pregnancy? G Chir. 2019 Mar-Apr;40(2):112-114.
4. Kapoor, S., Sivanesan, K., Veerasingham, M. Bakri Balloon- A Cautionary Tale. European Journal of Obstetrics & Gynecology and Reproductive Biology 221 (2018) 189-207
5. Lane WE1, Cobert J2, Horres CR2, Strouch Z3, Mehdiratta J3. Undetected uterine rupture during induction of labor for intrauterine fetal demise using epidural anesthesia. J. Clin Anesthesia 2019 Dec;58:20-21. doi: 10.1016/j.jclinane.2019.04.023. Epub 2019 May 1.
6. Leparco, S., Viot, A., Benachi, A., Deffieux, X. Migration of Bakri balloon through an unsuspected uterine perforation during the treatment of secondary postpartum hemorrhage. JUNE 2013 American Journal of Obstetrics & Gynecology
7. Mazzone ME, Woolever J. Uterine rupture in a patient with an unscarred uterus: a case study. WMJ. 2006;105(2):64- 66.
8. Mavromatidis, G., Karavas, G., Margioulas-Siarko, C., Petousis, S., Kalogiannidis, I., Mamopoulos, A., Rouso, D. Spontaneous Postpartum Rupture of an Intact Uterus: A Case Report. J Clin Med Res. 2015;7(1):56-58