

Subdural Hematoma Formation Following Incidental Dural Puncture and Intrathecal Catheter Placement

Jing Song, MD, Li Zhang, MD, Nora Martin, MD, Vilma Joseph, MD

DEPARTMENT OF ANESTHESIOLOGY, MONTEFIORE MEDICAL CENTER/ALBERT EINSTEIN COLLEGE OF MEDICINE, BRONX, NEW YORK.

BACKGROUND:

Subdural hematomas (SDH) are an extension postdural puncture headache (PDPH). The dural puncture leads to loss of cerebrospinal fluid and rupture of the intracranial veins.¹ The subdural bleed causes intracranial hypertension, which leads to symptoms that diverge from those of PDPHs. The headaches experienced become non-postural and focal neurological symptoms are present.

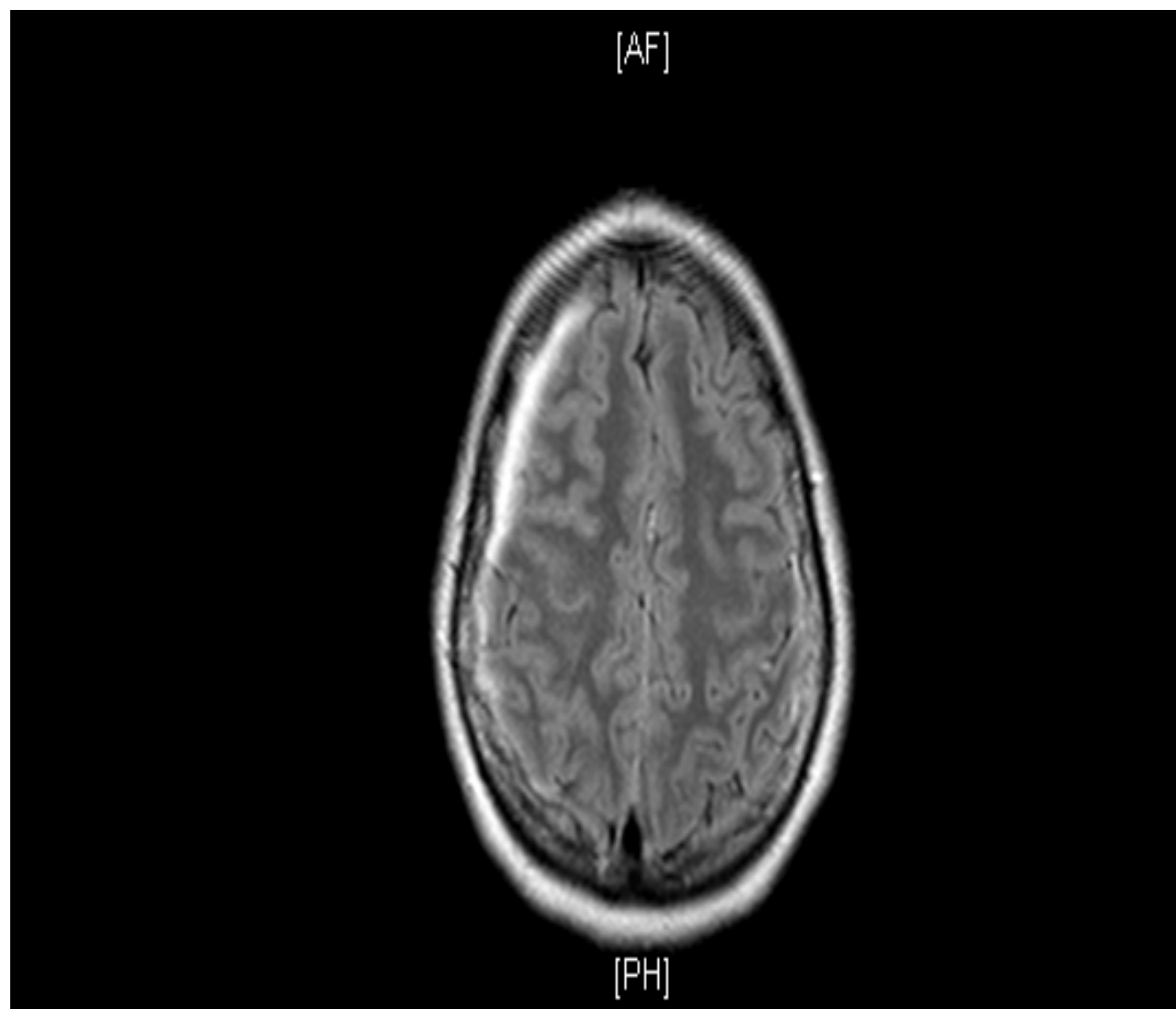


Figure 1. CT scan: Axial View of Head. A 6mm subdural hematoma is displayed in the right hemisphere.

CASE REPORT:

A 24 year old G1P0010 was induced at 38 weeks gestation due to gestational diabetes. She was given 1 liter bolus of crystalloid. A combined spinal-epidural (CSE) was attempted at the L3-L4 and L4-L5 spaces, but it was difficult due to undiagnosed scoliosis. The dura was accidentally punctured at L4 with 17G Touhy and an intrathecal catheter was placed. The intrathecal catheter was loaded with 5 ml of 0.25% bupivacaine and pain relief was achieved. A healthy baby was delivered 13 hours later. The estimated blood loss was 300 ml. On postpartum day 1, she had a 10/10 positional headache; it was worse in an upright position and better in supine position. The headache did not improve with acetaminophen. An epidural blood patch (EBP) was conducted at L4. Following the EBP, she had complete relief of her headache and was discharged the next day.

Her headache recurred after 24 hours of being discharged. She presented to the emergency room after 72 hours of unremitting 5/10 headache. The headache was still positional and associated with emesis and photophobia. Her vital signs were stable. A head CT was completed and it revealed a 6 mm right SDH with minimal mass effect. She was admitted to the ICU. Initially, she was managed conservatively. A second CT/MRI showed no change in size of the subdural hematoma. Due to the unremitting nature of the her headache, a second EBP was performed postpartum day 9. Following EBP, she had complete relief and recovery.

DISCUSSION:

There should be a low threshold for evaluation of subdural hematoma via CT with contrast or MRI in patients who have been previously diagnosed with PDPH and refractory to conservative therapy and EBP.^{3,4} We believe that a second EBP should be common practice in setting of a failed EBP, especially in patient who required multiple placement attempts in order to decrease the likelihood of possible subdural hematoma expansion.

REFERENCES:

1. Yamashima T, Friede RL. Why do bridging veins rupture into the virtual subdural space? *J Neurol Neurosurg Psychiatry*. 1984.
2. Bjärnhall M, Ekseth K, Boström S, Vegfors M. Intracranial subdural haematoma--a rare complication following spinal anaesthesia. *Acta Anaesthesiol Scand*. 1996.
3. Jack TM. Subdural haematoma as a complication of spinal anaesthetic. *Br Med J (Clin Res Ed)*. 1982.
4. Macon ME, Armstrong L, Brown EM. Subdural Hematoma following Spinal Anesthesia. *Anesthesiology*. 1990.