

# Hole in One: Use of Intubating LMA in an Emergency Cesarean Delivery

**Priyanka Patel, DO; Mark Stypula, MD; Erica Coffin, MD**  
 Department of Anesthesiology, Allegheny Health Network, Pittsburgh, PA

### Introduction

Difficult intubation for emergency cesarean delivery is associated with increased mortality and morbidity (1). It is well-known that as pregnancy progresses, the parturient airway becomes more challenging, and there have been multiple published articles discussing the management of difficult airways (Figure 1) (2). A retrospective study recently illustrated that laryngeal mask airway (LMA) is the most common airway rescue device utilized during a difficult airway in obstetric anesthesia. This study looked at the utility of the LMA and the subsequent consequences of its use (3). Here, we demonstrate the successful use of an intubating LMA during a difficult airway in an emergency cesarean section.

### Case Report

A 19 year old G1P0 at 30 weeks and 6 days was admitted for pre-eclampsia with severe features. A decrease in fetal heart rate was noted in triage and the patient was brought to the operating room for emergency cesarean delivery under general anesthesia. Rapid-sequence induction was initiated. Two attempts at video laryngoscopy failed due to poor visualization of airway structures. The surgery was started under straightforward bag-mask ventilation. An LMA was then placed without difficulty and ventilation was determined to be effective. The standard LMA was then successfully exchanged for a Fastrach intubating LMA. A 6.5mm endotracheal tube (ETT) was placed through the intubating LMA. The ETT position was confirmed and placement was secured. The patient was extubated uneventfully after the procedure and remained stable throughout the remainder of her admission.

### Discussion

Here, we demonstrated the use of an intubating LMA (Figure 2) in a can ventilate, cannot intubate situation. Previously, a case report described a similar situation in which a ProSeal LMA was utilized and an oral gastric tube was passed to aspirate stomach contents (4). Successful aspiration of gastric contents with a standard LMA has also been reported in the literature (3). The use of a more advanced LMA mitigates the risk of aspiration by allowing placement of an ETT, as described in this case report.

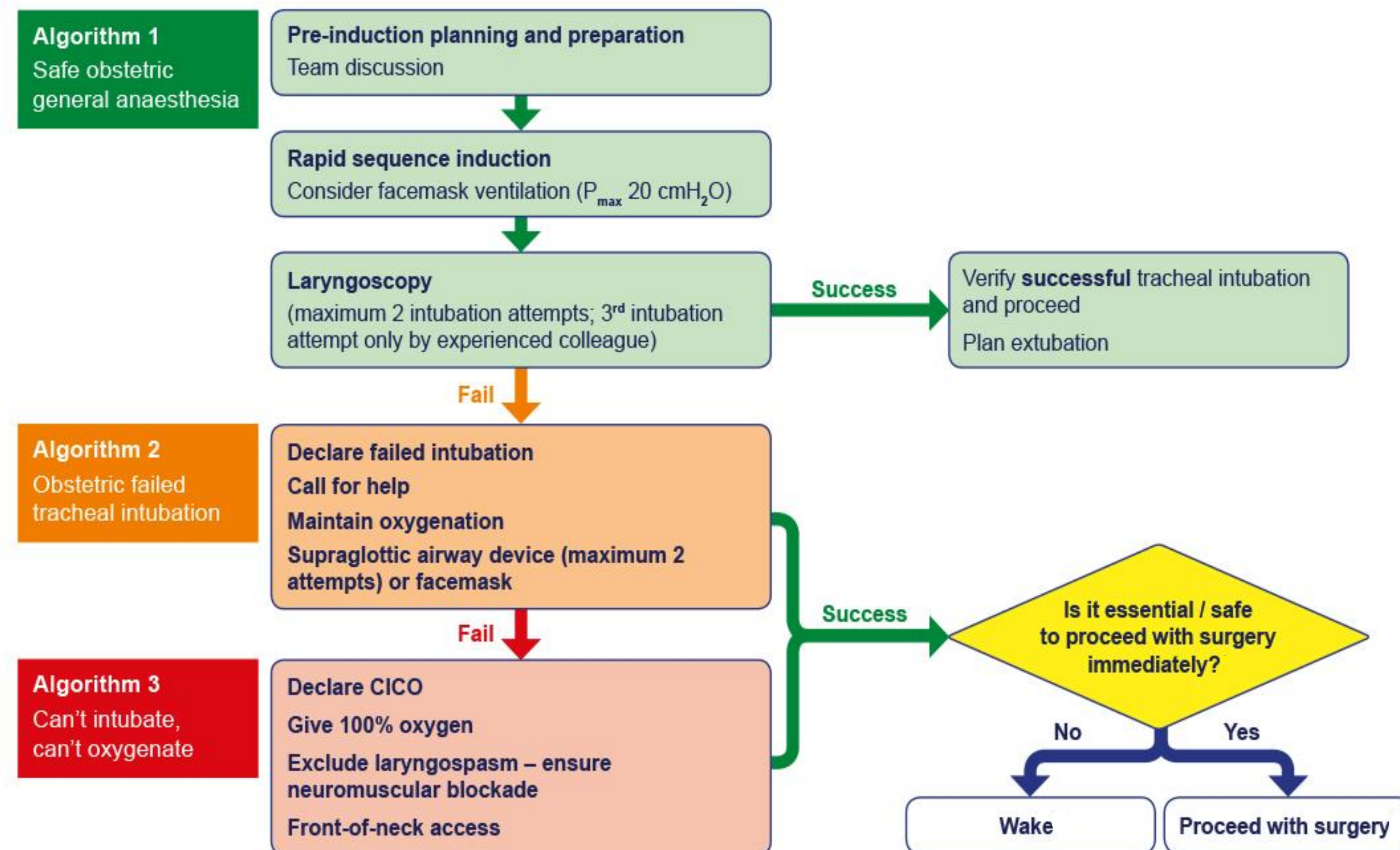
Figure 2



Figure 2: Left: Intubating LMA Right: Intubating LMA with stabilizing rod and endotracheal tube

Figure 1

### Master algorithm – obstetric general anaesthesia and failed tracheal intubation



© Obstetric Anaesthetists' Association / Difficult Airway Society (2015)



Figure 1: Reproduced from Mushambi MC, Kinsella SM, Popat M, Swales H, Ramaswamy KK, Winton AL, Quinn AC. Obstetric Anaesthetists' Association and Difficult Airway Society guidelines for the management of difficult and failed tracheal intubation in obstetrics. *Anaesthesia* 2015; 70: 1286 – 1306, with permission from Obstetric Anaesthetists' Association / Difficult Airway Society

### References

- 1). Basaranoglu G, Columb M, Lyons G. Failure to predict difficult tracheal intubation for emergency caesarean section. *Eur J Anaesthesiology*. 2010;27:947–9.
- 2). Vasdev GM., Harrison BA., Keegan MT. Burkle CM. Management of the difficult and failed airway in obstetric anesthesia. *J Anesth*. 2008;22:38–48.
- 3). Geng ZY, Wang DX. Laryngeal mask airway for cesarean delivery: a 5-year retrospective cohort study. *Chin Med J*. 2017;130:404–8.
- 4). Awan R, Nolan JP, Cook TM. Use of a ProSeal™ laryngeal mask airway for airway maintenance during emergency Caesarean section after failed tracheal intubation. *British Journal of Anaesthesia*. 2004;92:144-146.